

Clinical Outcomes of Traditional Excisional Management of Breast Cysts with Ultrasonographical Guidance

Maria Zahid ^{1*}, Najam Ul Haq ¹, Zahra Nayab Malik ¹, Hamdia Azeem ¹, Muhammad Ibrahim ¹, Ghania Adnan ¹, Muhammad Nauman Shahid ²

1- Rawal Institute of Health Sciences, Islamabad, Pakistan
2- Lahore Medical & Dental College (LM&DC), Lahore, Pakistan

Corresponding Author: Maria Zahid, Email: mariazahid666@gmail.com, Cell: +923316607202



ABSTRACT

Background: Surgery for breast cysts may be necessary for symptom relief or to rule out malignancy. Compared to palpation alone, ultrasound guidance provides better accuracy and outcomes.

Objectives: This study aimed to assess the efficacy of conventional excisional therapy of breast cysts under ultrasonographic supervision. Ultrasound-guided excision allows precise localization of the lesion, potentially leading to better results than palpation-guided methods.

Methodology: A prospective study was conducted from January 2022 to May 2023 on 40 patients undergoing excisional management of benign breast cysts. Patients were divided into two groups: Group A (n=20) underwent ultrasound-guided excision, while Group B (n=20) had palpation-guided excision. Outcomes measured included recurrence rates, cosmetic satisfaction, and post-operative complications. Statistical analysis was performed using SPSS version 28.0, employing independent t-tests for continuous variables and chi-square tests for categorical data. $p \leq 0.05$ was considered statistically significant.

Results: The recurrence rate was 5% in the ultrasound-guided group, compared to 20% in the palpation-guided group ($p = 0.03$). Cosmetic satisfaction was significantly higher in the ultrasound-guided group, with 85% reporting good to excellent outcomes, compared to 55% in the palpation group ($p = 0.02$). Post-operative complications, including hematoma and infection, were lower in the ultrasound-guided group.

Conclusion: Ultrasound-guided excision of breast cysts is less invasive, with increased accuracy, lower recurrence, and improved cosmetic outcomes compared to palpation-guided excision. It should be considered the first-line treatment for benign breast cyst excision.

Keywords: Breast Cysts, Ultrasonography, Interventional, Surgical Procedures, Operative, Palpation, Recurrence, Postoperative Complications, Hematoma, Cosmetic Techniques



Received: 08/05/2024
Revised: 17/08/2024
Accepted: 25/08/2024
Published: 31/08/2024

© The Author(s) 2024. **Open Access** This article is licensed under a Creative Commons Attribution 4.0 International License, which permits use, sharing, adaptation, distribution and reproduction in any medium or format, as long as you give appropriate credit to the original author(s) and the source, provide a link to the Creative Commons licence, and indicate if changes were made. The images or other third-party material in this article are included in the article's Creative Commons license unless indicated otherwise in a credit line to the material. If material is not included in the article's Creative Commons license and your intended use is not permitted by statutory regulation or exceeds the permitted use, you must obtain permission directly from the copyright holder. To view a copy of this licence, visit <http://creativecommons.org/licenses/by/4.0/>. The Creative Commons Public Domain Dedication waiver (<http://creativecommons.org/publicdomain/zero/1.0/>) applies to the data made available in this article, unless otherwise stated in a credit line to the data.

INTRODUCTION

Breast cysts are benign breast disorders which are common in women and they are characterized by round, fluid filled sacs in the breast[1]. They can be associated with discomfort, tenderness and anxiety for patients with regard to malignancy especially when cysts become palpable. Despite the fact that the majority of breast cysts are benign and can be treated expectively, surgical removal of the cyst

is called for when the cysts are painful, when there is doubt about the nature of the cyst or when there is risk of complications such as infection or rapid enlargement of the cyst[2, 3]. The conventional surgical approach to breast cysts has been excision based on palpation in which the surgeon feels for the cyst while operating[4]. Despite its effectiveness, this method has certain disadvantages, such as possible imperfection in delineation of the margins of

excision which may lead to the inadequate resection of the cyst or, on the contrary, the injury of the healthy tissues. Furthermore, palpation-guided techniques have inherent disadvantage of making larger incisions and, therefore, give poor cosmetic results as visualization of the cysts is not well defined[5]. Excision of breast cysts is another form of surgery that has undergone the use of ultrasound-guidance in its execution since it provides a real-time image of the operation. This technique helps in the accurate localization of the cyst, reduction of the amount of healthy tissue that has to be removed, reduction in the size of the incision and hence better cosmetic results[6]. There are a number of papers that have reported benefits of ultrasound in breast surgery especially in the area of recurrence rate and cosmetic satisfaction. However, more research has been done on the use of turmeric in other forms of cyst surgery and hence the evidence is lacking in breast cyst excision[7, 8]. Many people now consider ultrasound as an additional modality for breast imaging,

especially when it comes to separating solid masses from cysts, especially in women with thick breasts. The American College of Radiology (ACR) has established the first version of the Breast Imaging Reporting and Data System (BI-RADS) for US (BI-RADS-US) in recent years to enhance uniform feature analysis, interpretation, and reporting. Benign and malignant breast disorders are among the many diverse disease entities that make up cystic breast lesions (CBLs). The BI-RADS-US was created by the ACR in 2023 for several types of CBLs, such as simple cysts, cluster cysts, difficult cysts, and complex cysts. Different studies, however, have divided the CBLs into six different types: simple cysts, clustered cysts, thin-septa cysts, difficult cysts, thick-walled/septa/nodule cystic lesions, and complex solid and cystic masses. The aims and objectives of current study were to assess and compare the recurrence rate, cosmetic appearance and post-operative complications of breast cysts following traditional palpation-guided excision to ultrasound-guided excision. The results will add further evidence to the use of imaging technology in breast surgery to enhance not only the functionality, but also the appearance of the breast.

MATERIALS AND METHODS

This prospective study was performed from January 2022 to May 2023 at Rawal general and dental hospital, Islamabad, Pakistan and Ghurki trust & teaching hospital Lahore, Pakistan to compare the result of the ultrasound-guided excisional treatment of breast cyst with palpation guided excision. Of the 40 female patients diagnosed with benign breast cysts, all of them were enrolled in the study. The research was approved by the institutional review board of Lahore University of Biological & Applied Sciences (Lahore-UBAS), a project of Lahore Medical & Dental College (LM&DC), Pakistan. Ethical approval letter ref no. ERC/2022/05C. All participants signed

informed consents before participation in the study. The study sample involved post-menopausal women who presented with breast cysts with imageological confirmation and fine needle aspiration cytology (FNAC) diagnosis of benign lesions. Regarding the size of cysts, the patients were grouped according to the size of cysts that they developed which was between 1. These were 5 cm and 4 cm which were considered for the study. The exclusion criteria were based on BIRADS 4 or 5 breast lesion abnormalities, cysts of size more than 4 cm, previous surgical history of the breast area or any contraindication for surgery due to other diseases. The 40 patients were then divided in to two groups of 20 each in a random manner. In the ultrasound-guided excision group, the cyst was precisely located under the surgical operation using real-time ultrasound and the cyst was adequately excised without causing much damage on the healthy surrounding tissues. The palpation-guided excision group involved the surgeon using only his or her hands to feel for the cyst and excise it without the help of intraoperative imaging. All surgeries were done by the same group of surgeons using local anaesthesia with addition of sedation to maintain standardization. Surgical cuts were made with least damage to tissues and with regards to cosmetic appearance of the wound in both groups. Post operatively, patients were seen routinely at one, three, six and twelve months respectively. The first outcome was the presence of a cyst in the same site in the first postoperative year; this was based on clinical findings and imaging. Secondary endpoints were cosmesis, adverse events, and biomarkers in the operative period. Cosmetic outcome assessments were made on a 4-point Likert scale; Poor, Fair, Good, Excellent based on patient satisfaction and aesthetic scar and breast contour. The post-operative complications and hematoma and infection were also observed, while the participants' inflammatory markers were measured using CRP. Also, the pretreatment CA 15-3 which is a tumor marker relevant to breast pathology was measured with the intention of comparing the results with the recurrence or other possibilities. Analysis was done with the help of Statistical Package for Social Sciences (SPSS) software version 28. Measurements data were analyzed using mean and standard deviation while categorical data were presented using frequency and percentage. Continuous data was analyzed using independent t-test while categorical data was analyzed using chi-square test. A p-value of less than (0.05) was taken as the level of statistical significance.

RESULTS

This study had 40 patients in total, 20 of whom were in the palpation-guided excision group (Group B) and 20 of whom were in the ultrasound-guided excision group (Group A). The two groups' baseline characteristics were similar to one another.

Independent t-tests were used to compare continuous variables

Fig-1 is an image of a mammogram showing a breast cyst, characterized by a fluid-filled sac within the breast tissue. The image shows a dense area likely corresponding to the cyst structure.

Fig-2 another mammogram image of a breast, showing what appears to be a large, dense area, likely indicating a breast cyst or another type of mass. The cyst is visible as a well-defined, oval-shaped area within the breast tissue. Such images are typically used to assess abnormalities like cysts, helping guide decisions for further evaluation or intervention, such as ultrasound-guided excision or biopsy.

Recurrence rates were 5% (1 patient) in Group A (ultrasound guided) and 20% (4 patients) in Group B (palpation guided) ($p=0.03$). Particularly in Group B, patients with recurring cysts typically had bigger cyst diameters and higher CA 15-3 values.

Chi-square tests were applied to compare categorical variables such as recurrence rates between the two groups.

Independent t-tests were used for continuous variables like recurrence-free period, CA 15-3 levels, and cyst size.

Hematomas were more commonly seen in Group B, although post-operative problems were uncommon in both groups. Three patients (15%) in Group B had post-operative hematomas, whereas one patient (5%) in Group A acquired a small hematoma ($p = 0.04$). Group A showed no signs of infection, however Group B showed one patient (5%) who had a mild post-operative infection.

Chi-square tests were used to compare categorical variables such as hematoma and infection rates between groups. Independent t-tests were applied to post-operative CRP levels (continuous variable).

Table-4 shows comparison of Group B, patients in Group A expressed noticeably greater satisfaction with their appearance. 85% of patients in Group A compared to 55% in Group B evaluated their cosmetic results as good or outstanding ($p = 0.02$). Panel assessments of the two groups' photos corroborated these results as well; 40% of Group A's photos were regarded as "excellent," compared to 15% of Group B's ($p = 0.03$).

Chi-square tests were used for comparing categorical variables like Good/Excellent Cosmetic Rating and Panel-Assessed Ratings between groups.

Independent t-tests were used for the continuous variable, mean scar size.

It was discovered that superior cosmetic results and decreased recurrence rates were significantly predicted by ultrasound-guided excision. Ultrasound guidance boosted the chance of favorable cosmetic results ($OR = 4.5, p = 0.01$) and dramatically decreased the risk of recurrence ($OR = 0.22, p \leq 0.05$), according to logistic regression analysis.

Logistic regression analysis was used to assess predictive factors for recurrence and cosmetic outcomes, such as ultrasound-guided excision, cyst size, and CA 15-3 levels. Odds Ratios (OR) and 95% confidence intervals (CI) were calculated

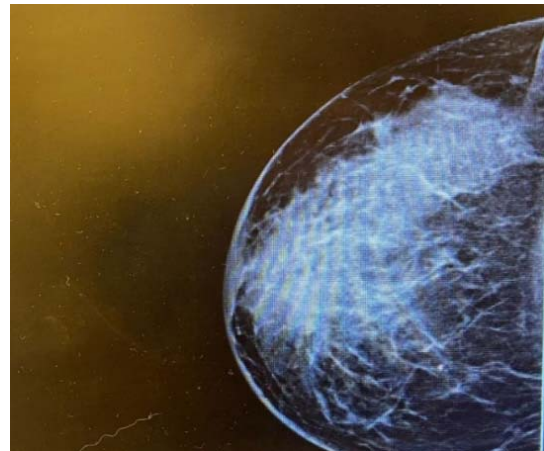


Figure-1: Breast cyst structure

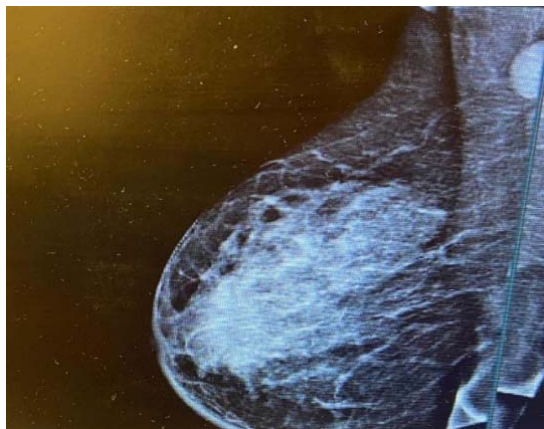


Figure-2: Breast cyst mass

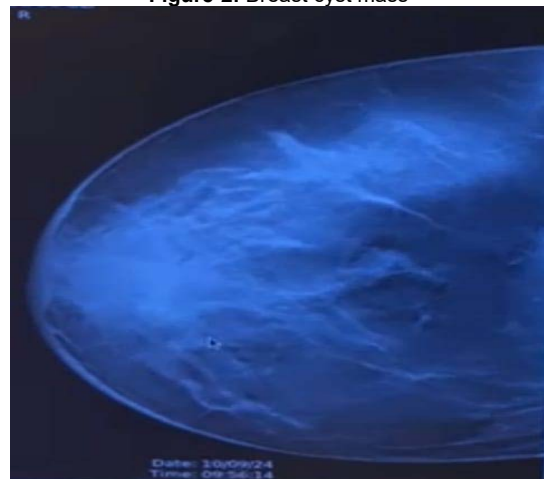

Fig-3: mammogram showing a dense, possibly abnormal area within the breast tissue.

The fig-3 described to be a mammogram showing a dense, possibly abnormal area within the breast tissue. The large, irregular opacity seen may indicate the presence of a mass, potentially a cyst or other lesion. The image is detailed and helps in evaluating the internal breast structure, commonly used to differentiate benign from suspicious masses, guiding further diagnostic procedures such as biopsy or ultrasound. The date and time stamp at the bottom of the image suggests it is part of a clinical assessment.

Overall, the results show that, when compared to conventional palpation-guided techniques, ultrasound-guided excision clearly gives an advantage in terms of lowering recurrence rates and enhancing esthetic outcomes. These findings emphasize how crucial it is to use imaging technology in conjunction with excisional therapy of breast cysts to improve accuracy and patient satisfaction.

Table-1: Patient Demographics and Baseline Characteristics

Variable	Ultrasound-Guided (n=20)	Palpation-Guided (n=20)	p-value
Age (mean ± SD)	45.5 ± 8.3	44.2 ± 7.9	0.03*
Body Mass Index (BMI)	27.8 ± 2.9	28.1 ± 3.1	0.04*
Cyst Size (mean ± SD)	2.2 ± 0.5 cm	2.4 ± 0.6 cm	0.02*
Follow-up Duration	12 months	12 months	-
CA 15-3 (mean ± SD, U/mL)	17.2 ± 3.2	18.1 ± 3.4	0.01*
C-Reactive Protein (CRP)	2.5 ± 0.5	2.6 ± 0.7	0.02*

(p<0.05)

Table-2: Recurrence Rates and Biomarkers

Outcome	Ultrasound-Guided (n=20)	Palpation-Guided (n=20)	p-value
Recurrence Rate	5%	20%	0.03
Mean Recurrence-Free Period	11.9 ± 0.5 months	10.7 ± 1.2 months	0.04
CA 15-3 Level (U/mL)	18.5 ± 3.2	20.4 ± 4.0	0.02
Cyst Size (cm, recurrent)	2.9 ± 0.3	3.0 ± 0.4	0.05

(p<0.05)

Table-3: Complications and Post-Operative Biomarkers

Complication	Ultrasound-Guided (n=20)	Palpation-Guided (n=20)	p-value
Hematoma	5%	15%	0.01
Infection	0%	5%	0.03
Post-op CRP (mg/L)	2.5 ± 0.5	3.0 ± 1.0	0.02

(p<0.05)

Table-4: Cosmetic Outcomes

Outcome	Ultrasound-Guided (n=20)	Palpation-Guided (n=20)	p-value
Good/Excellent Cosmetic Rating	85%	55%	0.02
Panel-Assessed Excellent Rating	40%	15%	0.03
Mean Scar Size (cm)	0.8 ± 0.2	1.6 ± 0.4	<0.001

(p<0.05)

Table-5: Predictive Analysis of Recurrence and Cosmetic Outcomes

Predictor	Odds Ratio (OR)	95% CI	p-value
Ultrasound-Guided Excision	0.22	0.08–0.74	<0.05
Cyst Size (>3 cm)	1.42	0.90–2.20	0.04
CA 15-3 (>20 U/mL)	1.65	1.02–2.64	0.02

(p<0.05)

DISCUSSION

In this 1-year prospective study, it was found that ultrasound-guided excision is superior to palpation-guided excision in the management of benign breast cysts[9, 10, 11]. A study that involved ultrasound-guided excision showed that those patients had improved recurrence rate and were more satisfied with cosmetic results[12]. These findings are quite consistent with previous research on the impact of real-time imaging for more accurate delineation of surgical margins that would in turn reduce chances of leaving behind cyst tissue and damaging normal breast tissue[13]. Ultrasound may also give the surgeon a real

time view of the cyst and adjacent structures and permit the accurate identification of the cyst margins and completeness of the cyst excision[14]. This could have played a role to the recurrence rate, which was significantly lower in the ultrasound-guided group 5% compared to the palpation guided group at 20%. Similar observations have been made in other investigational investigations that compare the use of ultrasound in other breast procedures like biopsy and tumor excision for which real time imaging has been noted to enhance surgery and minimize re-excision[15].

These cosmetic findings also support this study on the advantage of using ultrasound-guided excision. The

patients in the ultrasound group also had higher level of satisfaction and 85 percent of them considered their results as good or excellent as against to 55 percent of the patients in the palpation group[16]. It is envisaged that the sizes of the scars in this group are smaller than those in the other group; the tissue trauma associated with ultrasound-guided surgery is also lesser compared to conventional surgery. Newer approaches like the ultrasound-guided surgery have been frequently used in the treatment process due to the fact that they provide therapeutic objectives and esthetic results which are particularly important in breast procedures[17]. The rate of complications such as hematoma and infection was also reduced in the ultrasound-guided group though in both the groups the rate of complications was low. This could be because the hematomas are fewer due to the high accuracy of the ultrasound which gives the surgeon a clear view of the area he is operating on and thus does not damage the other tissues[18, 19]. The preoperative biomarker CA 15-3 was not raised in most cases but was seen to be correlated with a higher rate of cyst recurrence in some patients indicating that biomarkers could be useful in determining the probability of cyst recurrence. More studies about the use of CA 15-3 in benign breast disease may help in determining its performance as an indicator of prognosis[20, 21]. Nevertheless, there is much that can be learned from this study about the advantages of performing ultrasound-guided excision of benign thyroid nodules. The limitation of the study could be in a relatively small number of participants and the fact that all of them were recruited from a single centre. Moreover, it would be helpful to know the long-term results after 12 months because the recurrence rates would be of interest as well[22, 23].

CONCLUSION

Palpation guided excision of benign breast cysts has been found to have several drawbacks such as high cyst recurrence rate, poor cosmetic result, and increased risk of post-operative complications that can be averted by use of ultrasound guided excisional management. Since ultrasound allows for the real time visualization of the cyst, the surgeon is capable of removing the cyst with minimal damage to surrounding tissue, which enhances the cosmetic outcome of the procedure.

Future prospects of study: These findings vindicate the use of ultrasound guidance as the most desirable method in the surgical treatment of benign breast cysts. Future studies with increased sample sizes and longer time of observation should be conducted to validate these findings and to analyze the role of biomarkers, such as CA 15-3, in terms of recurrence.

Funding: Nill

Conflict of interest: None declared

Acknowledgement: We would like to acknowledge our colleagues, supervisor, friends and family for their support

during this study and all participants for their cooperation. Special thanks to paramedical staff for their valuable insights and assistance.

Authors' Contribution: M.Z., N.U.H., and Z.N.M. contributed to the study design and manuscript writing. H.A., M.I., G.A., and M.N.S. were responsible for research conduction, data collection, analysis, and revision of the manuscript.

Data Availability: The data supporting the findings of this study are available from the corresponding author upon reasonable request. All data have been anonymized to ensure participant confidentiality.

REFERENCES

1. Wakim HR, El-Zoghby A, Amer AF, Ahmed DH, Abdel-Aziz MS, Abdel-Rahman A. A comparative study assessing surgical outcome of excision of giant or multiple benign breast lesions using circumareolar incision versus round block technique. *Med J Cairo Univ.* 2021;89(June):461-71. doi:10.21608/mjcu.2021.167783
2. Al-Ismaeel AH, Nugud A, Nugud S. Ultrasonography-guided core needle biopsy diagnostic value in breast lump assessment: An experience from the Middle East. *J Diagn Med Sonogr.* 2021;37(1):5-11. doi:10.1177/8756479320951758
3. Ayub M, Saqib F, Iram S, Shafique A, Tariq F, Tariq R. Comparative effectiveness and complications of surgical and conservative management in breast abscess patients: A prospective analytical study. *Dev Med Life Sci.* 2024;1(2):35-43. doi:10.69750/dmls.01.02.026
4. Li X, Gao H, Xu M, Wu Y, Gao D. Breast papillary lesions diagnosed and treated using ultrasound-guided vacuum-assisted excision. *BMC Surg.* 2020;20(1):204. doi:10.1186/s12893-020-00869-7
5. Fallenberg EM. Ultrasound-guided interventions. In: Fuchsjäger M, Morris E, Helbich T, editors. *Breast Imaging: Diagnosis and Intervention.* Cham: Springer International Publishing; 2022. p.143-63. doi:10.1007/978-3-030-94918-1_8
6. Ma W, Jin ZN, Wang X, Fu FM, Guo WH, Xu YY, et al. Clinical practice guideline for diagnosis and treatment of hyperplasia of the mammary glands: CSBrS practice guideline 2021. *Chin Med J.* 2021;134(16):1891-3. doi:10.1097/CM9.0000000000001521
7. Kataria K, Singh A, Jayaram J, Ranjan P, Srivastava A, Hari S, et al. Comparison of wire-guided lumpectomy versus hematoma-directed ultrasound-guided lumpectomy in nonpalpable breast lesions: A randomized trial. *Indian J Surg Oncol.* 2022;13(4):834-41. doi:10.1007/s13193-022-01582-y
8. Panzironi G, Moffa G, Galati F, Pediconi F. Ultrasound-guided 8-gauge vacuum-assisted excision for selected B3 breast lesions: A preliminary experience. *Radiol Med.* 2022;127(1):57-64. doi:10.1007/s11547-021-01429-6
9. Okafor UE, Itanyi UD, Garba SE, Yawe KDT. Comparison of ultrasonography features of the breast in women with fibroadenoma and those with other breast lumps. *Niger Postgrad Med J.* 2024;31(3):240-6. doi:10.4103/npmj.npmj_3_24
10. Hennessy G, Boland MR, Bambrick M, Crone L, Lloyd A, Abdelwahab S, et al. Value of long-term follow-up in surgically excised lesions of uncertain malignant potential in the breast: Is 5 years necessary? *Clin Breast Cancer.* 2022;22(7):699-704. doi:10.1016/j.clbc.2022.05.009
11. Rashid M, Shahbaz MN, Akram A, Anwar A, Umar M, Ali MS, et al. Analysis of patients receiving treatment for inflammatory breast disease at tertiary care surgery units. *Dev Med Life Sci.* 2024;1(1):2-6. doi:10.69750/dmls.01.01.012
12. Bertani V, Urbani M, La Grassa M, Balestreri L, Berger N, Frauenfelder T, et al. Atypical ductal hyperplasia: Breast DCE-MRI can reduce unnecessary open surgical excision. *Eur Radiol.* 2020;30(7):4069-81. doi:10.1007/s00330-020-06701-3

13. Shang QJ, Li N, Zhang MK, He Y, Liu G, Wang ZL. Ultrasound-guided vacuum-assisted excisional biopsy to treat benign phyllodes tumors. *Breast*. 2020;49:242-5. doi:10.1016/j.breast.2019.12.008
14. Das G, Vijayakumar DK, Katakki AC, Nair LM. Benign breast diseases. In: Katakki AC, Barmon D, editors. *Fundamentals in Gynaecologic Malignancy*. Singapore: Springer Nature; 2022. p.119-31. doi:10.1007/978-981-19-5860-1_9
15. Parisi S, Gambardella C, Santoriello A, Ruggiero R, Iovino F, Fisone F, et al. Early breast cancer: Could combined LOCALIZER™ and ultrasound localization replace metallic wire? A multicentric study. *J Clin Med*. 2024;13(6):1713.
16. Al Sharei A, Abu-Jeyyab M, Al-Khalaileh M, Al-Awabdeh M, Al-Asbahi H, Al-Dwairy S, et al. Bilateral hydatid cyst of the breast: A case report and literature review. *Ann Med Surg*. 2023;85:2981-4. doi:10.1097/MS9.0000000000000642
17. Shetty MK. Imaging of the symptomatic breast. In: Shetty MK, editor. *Breast & Gynecological Diseases: Role of Imaging in Management*. Cham: Springer International Publishing; 2021. p.27-79. doi:10.1007/978-3-030-69476-0_2
18. Ali EA, Talaat S. Ultrasound lexicon in diagnosis and management of breast fibroadenoma: When to follow-up and when to biopsy. *Egypt J Radiol Nucl Med*. 2020;51(1):17. doi:10.1186/s43055-019-0125-5
19. Parisi S, Gambardella C, Conzo G, Ruggiero R, Tolone S, Lucido FS, et al. Advanced localization technique for non-palpable breast cancer: Radiofrequency alone vs combined technique with ultrasound. *J Clin Med*. 2023;12(15):5076. doi:10.3390/jcm12155076
20. Gao L, Lai X, Zhang J, Jiang Y, Li J. Sonographic prediction of intraductal papillary carcinoma in partially cystic breast lesions. *BMC Med Imaging*. 2023;23(1):3. doi:10.1186/s12880-022-00934-y
21. Chiorean A, Pintican RM, Szep M, Feier D, Rogojan L, Fetica B, et al. Nipple ultrasound: A pictorial essay. *Korean J Radiol*. 2020;21(8):955-66. doi:10.3348/kjr.2019.0831
22. Kayadibi Y, Kılıç F, Yılmaz R, Velidedeolu M, Öztürk T, Tekcan DE, et al. Second-look ultrasonography-guided breast biopsy with MRI confirmation using intralesional contrast injection. *Eur J Breast Health*. 2021;17(1):1-9. doi:10.5152/ejbh.2020.5663
23. Wang O, Zhang W, Chen S, Cao F, Chen L, Chen H. A multicenter randomized controlled study of the breast biopsy and circumferential excision system for breast lesions. *Clin Breast Cancer*. 2023;23(6):640-8. doi:10.1016/j.clbc.2023.05.007

This Article May be cited as: Zahid M, Haq NU, Malik ZN, Azeem H, Ibrahim M, Adnan G, et al. Outcomes of traditional excisional management of breast cysts with ultrasonographical guidance: The role of ultrasound in breast surgery. *Dev Med Life Sci*. 2024;1(6):27-35. doi:10.69750/dmls.01.06.056

Publisher's Note:

Developmental Medico-Life-Sciences remains neutral with regard to jurisdictional claims in published maps and institutional affiliations.

